



NICOLAS LUZ SILVEIRA MANICA

**AVE ISQUÊMICO EM PACIENTE JOVEM ASSOCIADO A ENDOCARDITE INFECCIOSA:  
UM RELATO DE CASO**

Trabalho de Conclusão de Curso apresentado ao curso de graduação em Medicina da Universidade do Planalto Catarinense como requisito parcial à aprovação na Unidade Educacional Eletivo do 2022 Orientador: Prof. Rafael Frizon (Esp. Neurologista).

LAGES

2022

## Sumário

<b>RESUMO.....</b>	<b>3</b>
<b>Abstract: .....</b>	<b>4</b>
<b>Section 1 .....</b>	<b>4</b>
<b>Questions for consideration .....</b>	<b>5</b>
<b>Section 2 .....</b>	<b>5</b>
<b>Discussion .....</b>	<b>5</b>
<b>Conclusion.....</b>	<b>6</b>
<b>References .....</b>	<b>6</b>
<b>Comprovante de recebimento do artigo (TCC) pela revista: 8</b>	

## RESUMO

O presente estudo consiste no Trabalho de Conclusão de Curso de Medicina da Universidade do Planalto Catarinense. Trata-se de um relato de caso clínico que foi vivenciado pelo acadêmico durante os seus estágios em campo. O objetivo é elucidar alguns conceitos fisiopatológicos e terapêuticos relacionados com o acontecimento de Acidente Vascular Encefálico (AVE) isquêmico associado com Endocardite Infecciosa em pacientes jovens. A metodologia ocorrerá por meio da revisão de prontuários eletrônicos que contenham a história clínica detalhada dos eventos patológicos a serem relatados. A discussão se dará pela revisão de literatura do tema proposto com base em artigos atualizados disponíveis em bases de dado na internet como Scielo, PubMed e Google acadêmico, a fim de embasar cientificamente as informações apresentadas, sempre comparando com as que foram realizadas na prática. A Endocardite Infecciosa por si só é um importante fator de risco para eventos vasculares devido à presença de massas ou vegetações nas cavidades cardíacas, as quais podem promover eventos emboligênicos, alterações na dinâmica de fluxos sanguíneos e consequentemente causar lesões no epitélio vascular. Esses três fatores compõem a clássica tríade de Virchow, segundo a qual a presença desses fatores leva a um aumento considerável do risco de se ter um evento agudo vascular. Sendo assim o presente relato visa incentivar uma investigação mais assídua de eventos neurovasculares, dentre eles o AVC isquêmico, em pacientes que apresentam um diagnóstico prévio ou de base de uma endocardite infecciosa. Esse relato de caso será entregue na forma de um Artigo científico com a finalidade de ser publicado em uma revista científica da área da neurologia.

**Palavras-chave:** endocardite infecciosa; AVE; tríade de Virchow; neurovascular; vegetações.

**Título: AVE ISQUÊMICO EM PACIENTE JOVEM ASSOCIADO A ENDOCARDITE INFECCIOSA: UM RELATO DE CASO.**

Autores: Nicolas Luz Silveira Manica, Rafael Frizon

Enviou para: Neurology

**Abstract:**

In Emergency is common evaluating patients with a hemibody deficit. In this case a 29-year-old, man, was admitted in a Emergency Service with an intense holocranial headache associated with right hemiplegia and right hemianesthesia, that has begun two days before the admission. The patient had a regular general condition, was confused and disoriented, Glasgow Coma Scale 14, anisocoric and with no meningeal signs. A investigation was made to found a diagnosis witch must be made with inflammatory, metabolic and infectious diseases like reversible cerebral vasoconstriction syndrome, cerebral vasculitis, Stroke and Infective endocarditis. But only after had received discharge, the diagnosis has been made by a transesophageal echocardiogram that showed a mitral valve vegetation suggesting Infective endocarditis. This case highlights the diagnostic of Infective endocarditis in a young man with Acute Ischemic Stroke suggesting a relationship between these diseases, that affects the Virchow's triad.

**Section 1**

A 29-year-old, man, previously healthy, was admitted in a Emergency Service with an intense holocranial headache associated with right hemiplegia and right hemianesthesia, and an onset of two days before the hospital admission. On first examination the patient had a regular general condition, was confused and disoriented, Glasgow Coma Score of 14, anisocoric (larger right pupil), no meningeal signs and showed a right hemibody motor deficit with upper body predominance. A cranial CT scan was performed, and no signs of ischemic and hemorrhagic lesions was found. Metabolic, infectious, and inflammatory tests were requested but showed no alterations. On the second day of hospitalization, they presented a sensitive aphasia, but with spontaneous reversion. CFS was collected for analysis but showed no alterations. A NMR scan was performed showing a diffusion restriction area in the left fronto-temporal lobe and a hypersign in flair, in the Left Middle cerebral artery (M3-M4 segments). Transthoracic echocardiogram presented heart chambers with normal diameter, normal systolic and segmentar functions, normal left ventricle function, lower mitral insufficiency, left atria with 41mm<sup>3</sup> and Ventricular ejection fraction of 65%. Ressonance angiography identified intense stenosis of the left internal carotid artery, complemented by a vessel wall resonance showing impregnation in the left supraclinoid artery, with homogeneous and concentric aspect and signs of subocclusion of the left middle cerebral artery with flow-void of the left intracavernous internal carotid artery. Slow flow in the distal segment of the middle cerebral artery with important leptomenigeal dilatation in the territory of left middle cerebral artery. Patient was instructed to maintain

ambulatory follow up with a neurologist and rheumatologist and to perform a transesophageal echocardiogram - which eventually identified a mitral valve vegetation with higher mitral thickness and reflow by doppler.

The patient was eventually hospitalized again and diagnosed with infective endocarditis, receiving antibiotic therapy with ceftriaxone 500mg IV once a day; oxacillin 500mg every four hours for 45 days, and gentamicin 80mg every eight hours for 10 days. After treatment and without any other complication, they received discharge for outpatient follow up with neurologist and rheumatologist care.

### Questions for consideration

1. What is the localization of his presentation?
2. What are the differential diagnoses?

### Section 2

In that case the clinical presentation occurs by the involvement of the left middle cerebral artery in segments M3-M4, so the patient presented hemiplegia and hemianesthesia in the right arm and in the right leg with upper predominance confirming the arterial territory involvement, and anisocoria with larger right pupil, without meningeal signs.

The differential diagnosis must be made with inflammatory, metabolic and infectious diseases like reversible cerebral vasoconstriction syndrome, cerebral vasculitis, Stroke and Infective endocarditis.

### Discussion

Infective endocarditis is a lethal disease caused by various pathogens like bacteria, fungi and rickettsias that directly infect the heart valves and myocardium progressively degenerating cardiac structures.<sup>6</sup>

*Staphylococcus sp.*, most related with medical procedures and hospital care, has surpassed the *Streptococcus sp.* as the principal pathogen that causes infective endocarditis, but the latter is yet the commonest in underdeveloped countries.<sup>6</sup>

For young patients, this disease is one of the most common causes of Acute Ischemic Stroke due to cardioembolic events, in which a detachment of a thrombus in the heart valves-

committed by the pathogen- occurs and migrates to a cerebral vascular territory and causes an acute arterial occlusion.<sup>5</sup>

The risk of an Acute Ischemic Stroke is related to a valve disease, fibrillation and cardiac prosthesis. These factors influence directly in the Virchow's triad, prompting blood flow alterations leading to vascular endothelial lesions, and causing blood coagulability alteration, propitiating a higher thrombogenicity and stasis of the blood.

## Conclusion

Recent articles show an increasing incidence of Acute Ischemic Stroke in young people around the world, this occurs in parallel with more evident risk factors. In this context, Infective endocarditis is a determinant risk factor of cardiovascular disease in young patients in consequence of vegetations present in the heart chambers, causing alterations in the dynamic of blood flow.

So, this case report shows the importance of complementary investigations of cerebrovascular disease in young patients, alerting for all healthy professionals to investigate possible relationships between these and infective endocarditis.

## References

1.CAO, GF., LIU, W., CAO, L. *et al.* **Stroke in patients with prosthetic valve endocarditis.** *Herz* **45**, 72–77 (2020). Disponível em: <https://doi.org/10.1007/s00059-019-4809-4>. Acesso em: 30 jun. 2022.

2.EKKER, Merkel S. et. al. **Epidemiology, aetiology, and management of ischaemic stroke in young adults.** *Lancet Neurol*, 2018; 17: 790-801. Disponível em: [https://www.thelancet.com/journals/laneur/article/PIIS1474-4422\(18\)30233-3/fulltext](https://www.thelancet.com/journals/laneur/article/PIIS1474-4422(18)30233-3/fulltext). Acesso em: 30 jun. 2022.

3.HATHIDARA, M.Y., SAINI, V. & MALIK, A.M. **Stroke in the Young: a Global Update.** *Curr Neurol Neurosci Rep* **19**, 91 (2019). Disponível em: <https://doi.org/10.1007/s11910-019-1004-1> Acesso em 30 jun. 2022

4.PUTAALA, Jukka. **Ischemic Stroke in Young Adults.** *Continuum (Mineap minn)* 2020; 26 (2, cerebrovascular disease): 386-414. Disponível em: [https://journals.lww.com/continuum/Abstract/2020/04000/Ischemic\\_Stroke\\_in\\_Young\\_Adult\\_s.11.aspx](https://journals.lww.com/continuum/Abstract/2020/04000/Ischemic_Stroke_in_Young_Adult_s.11.aspx) Acesso em: 30 jun. 2022

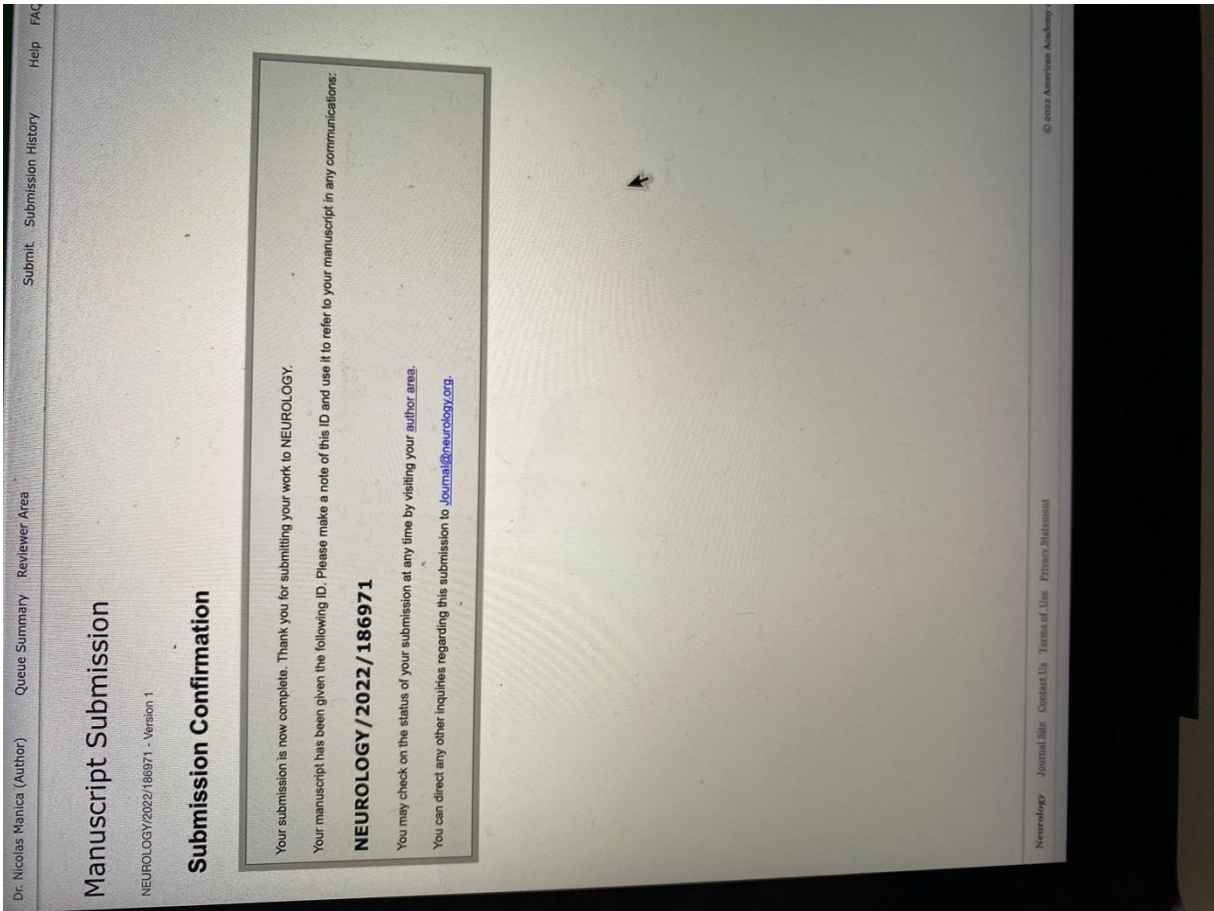
5.RAVELOSAONA, F. N. et. al. **Broad ischemic stroke revealing infective endocarditis in a young patient: about a case.** *Pan African Medical Journal.* 2016; 25:31. Disponível em: <https://www.panafrican-med-journal.com/content/article/25/31/full/> Acesso em 8 jun. 2022.

6.REN, Zuning et. al. **A changing profile of infective endocarditis at a tertiary hospital in China: a retrospective study from 2001 to 2018.** *BMC infectious diseases.* 2019 19:945. Disponível em: <https://bmcinfectdis.biomedcentral.com/articles/10.1186/s12879-019-4609-8>. Acesso em 8 jun. 2022.

7.SOUIRTI, Zouhayr et. al. **Infectious endocarditis complicated by an ischemic stroke and revealing Marfan syndrome.** *Journal of Cardiovascular Disease Research* vol. 2. N 2. 2011. Disponível em: <https://www.sciencedirect.com/science/article/abs/pii/S0975358311220084> Acesso em 8 jun. 2022.

8.VALENZUELA, Ives et. al. **Clinical risk factors for acute ischaemic and haemorrhagic stroke in patients with infective endocarditis.** *Intern Med J.* 2018 Sep;48(9):1072-1080. doi: 10.1111/imj.13958. Disponível em: <https://pubmed.ncbi.nlm.nih.gov/29740951/> Acesso em 8 jun. 2022.

**Comprovante de recebimento do artigo (TCC) pela revista:**







**J** **Journal@neurology.org** 17:49  
NEUROLOGY Manuscript Submission  
Caixa...-Exchange  
Para: Nicolas Mânica, Cc: rafael.frizon@hotmail.com [Detalhes](#)

NEUROLOGY MS ID#: NEUROLOGY/2022/186971  
MS TITLE: Clinical Reasoning: Acute Ischemic Stroke in a young patient in association with infective endocarditis

Dear Dr. Mânica:

The above mentioned manuscript has been submitted to NEUROLOGY by the Corresponding Author. If you did not approve the submission, please contact the Editorial Office immediately at [journal@neurology.org](mailto:journal@neurology.org).

Your manuscript will go through an initial screening for required material. If additional information is required, the corresponding author will be contacted. Otherwise, the manuscript will be assigned to an Associate Editor.

Please use the assigned manuscript number in all further correspondence. We will contact you once the review process has been completed.

Be sure to visit [NFub.org/submit](https://neurology.org/submit) and log in to your Author Area. Once logged in, you may check on the status of your manuscript.

If you have any questions or concerns about your paper, do not hesitate to contact us by e-mail: [journal@neurology.org](mailto:journal@neurology.org) or by phone: (612) 928-6400.

If you've uploaded figures for which you indicated that you do not own the copyright, you will be required to obtain permission to reprint the figure(s) from the current copyright holder before publication.

Thank you for giving NEUROLOGY this opportunity to consider your work.

Sincerely,

NEUROLOGY Editorial Office

Neurology®  
201 Chicago Ave  
Minneapolis, MN 55415  
tel. (612) 928-6400  
fax (612) 454-2748

NOTICE: This message may contain confidential or legally privileged information intended only for the use of the addressee(s) named above. Unauthorized use, disclosure, distribution, or copying is prohibited. If you have received this message in error, please reply to the sender and delete the original message. Thank you.